

Dental Consultant Initial Criteria Training:

 HCS | Medi-Cal Dental

Scaling and Root Planing
D4341 D4342

Presented By:
Trevor Miller, DMD



Procedure Codes Addressed

This training addresses Scaling
and Root Planing
(D4341 and D4342) only



Scaling and Root Planing

Objective:

Train new dental consultants on criteria for D4341 and D4342, namely that the procedures are a benefit when:

Evidence demonstrates that the member can be diagnosed with periodontitis

Which is to say ...

There are root surfaces clinically available that can be planed

Establishing this diagnosis can be tricky, so let's agree on some definitions:



Definitions

Gingivitis

Periodontitis

Prophylaxis

Scaling and
Root Planing

Pseudopocket

Clinical
Attachment
Level



Definitions

Periodontitis

Prophylaxis

Scaling and
Root Planing

Pseudopocket

Clinical
Attachment
Level

Gingivitis

swelling of the gums. Signs of gingivitis can include bleeding on probing, “puffy” gums, or pain on performing oral hygiene. Gingivitis is a **reversible** condition that is resolved when local irritants such as plaque and calculus are removed.



Definitions

Gingivitis

Prophylaxis

Scaling and
Root Planing

Pseudopocket

Clinical
Attachment
Level

Periodontitis

an inflammatory disease of supporting tissues of teeth caused by specific microorganisms or groups of specific microorganisms, resulting in progressive **destruction of the periodontal ligament and alveolar bone** with periodontal pocket formation, gingival recession or both



Definitions

Gingivitis

Periodontitis

Scaling and
Root Planing

Pseudopocket

Clinical
Attachment
Level

Prophylaxis

the preventive dental procedure of coronal scaling and polishing which includes the **complete** removal of calculus, soft deposits, plaque, stains and smoothing of unattached tooth surfaces

Even teeth with large, tenacious calculus deposits fall into this category so long as the calculus is on the enamel and not on the cementum



Definitions

Gingivitis

Periodontitis

Prophylaxis

Pseudopocket

Clinical
Attachment
Level

Scaling and Root Planing

a procedure that involves instrumentation of the crown and root surfaces of the teeth to remove plaque and calculus from these surfaces. It is indicated for patients with periodontal disease and is therapeutic, not prophylactic, in nature.



Definitions

Gingivitis

Periodontitis

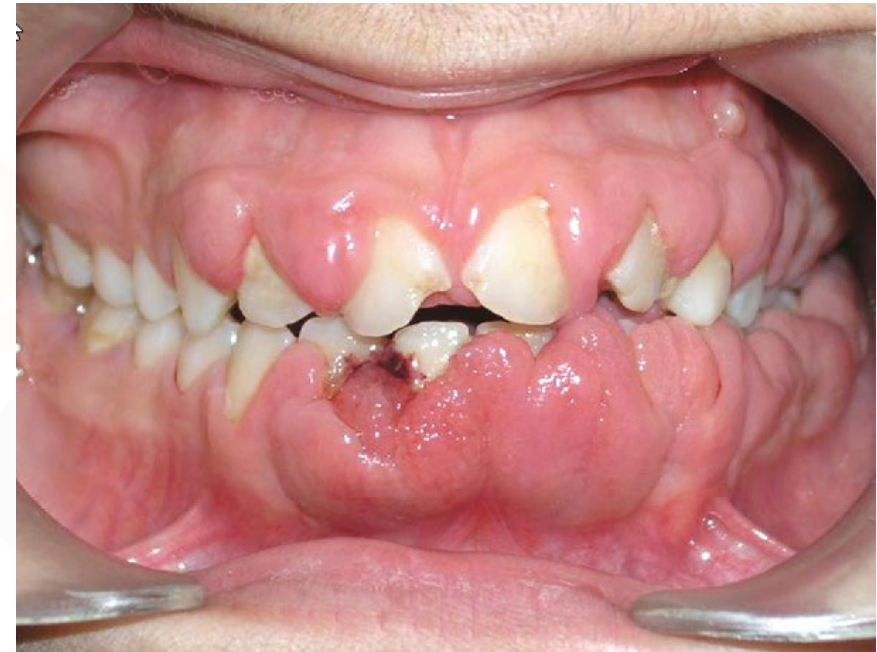Prophylaxis

Scaling and
Root Planing

Clinical
Attachment
Level

Pseudopocket

A deepening of the gingival crevice resulting primarily from an increase in bulk of the gingiva without apical migration of the junctional epithelium or appreciable destruction of the underlying tissue



Definitions

Gingivitis

Periodontitis

Prophylaxis

Scaling and
Root Planing

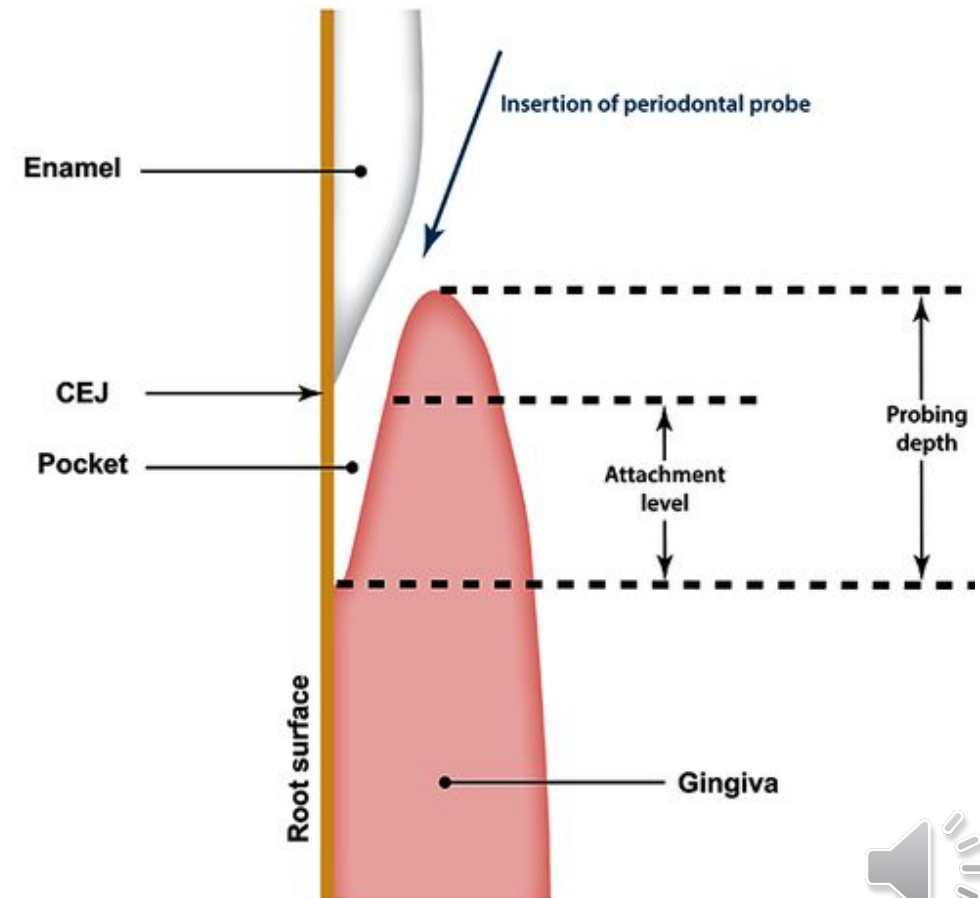
Pseudopocket

Clinical Attachment Level

The distance from the CEJ to the bottom of the sulcus or pocket

When the gingival crest is coronal to the CEJ, the CAL will be smaller than the probing depth

In the presence of gingival recession, the CAL will be greater than the probing depth



Definitions

Gingivitis



Periodontitis

Not the same thing



Definitions

It is easy to confuse gingivitis and periodontitis, but per these definitions:

Individuals can exhibit gingivitis *without* periodontitis



This means that bleeding on probing, swollen gums, pain when performing oral hygiene are not necessarily indicators of periodontitis

Individuals can exhibit periodontitis *without* gingivitis



This means that bone loss can be evident on radiographs and the member can qualify for therapeutic procedures such as D4341/D4342 even in the absence of gingivitis

Individuals can exhibit periodontitis *and* gingivitis

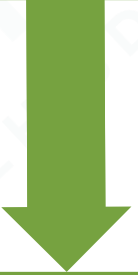

Radiographs and possibly photographs will **demonstrate bone loss**





Healthy Gums and Bone



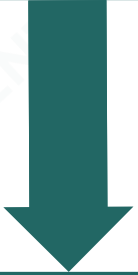Prophylaxis

Gingivitis Only



Prophylaxis

Periodontitis with or without Gingivitis



Scaling and Root Planing



Prophylaxis



Periodontal Maintenance

Medi-Cal Dental covers these periodontal procedures based on the member's diagnosis as determined via the provider's submission



Reminder: Prior authorization is required for Scaling and Root Planing except for

- pregnant/postpartum members
- special needs individuals whose treatment is rendered under general anesthesia

For more on Pregnant/Postpartum members, see C-DEN-TRN-109

For more on Regional Center Clients, see C-DEN-TRN-124

How does Medi-Cal Dental decide when Scaling and Root Planing is a benefit?





How does Medi-Cal Dental decide when Scaling and Root Planing is a benefit?

The principal piece of evidence evaluated is **radiographs**

Required radiographs include periapical radiographs of the involved areas and bitewings

Radiographs are evaluated for evidence of bone loss

Calculus is considered if it is **clearly on cementum** – calculus on enamel or at the CEJ is not necessarily an indication of bone loss





How does Medi-Cal Dental decide when Scaling and Root Planing is a benefit?

Radiographs are evaluated for Arch Integrity

Will this arch require a complete denture within five years?
see C-DEN-TRN-101

Teeth in the requested quadrant are evaluated for
restorability

Teeth that require extraction are not counted as qualifying

Periodontal probing chart can optionally be submitted

The readings should agree with the radiographs





How does Medi-Cal Dental decide when Scaling and Root Planing is a benefit?

Qualifying teeth per quadrant are counted

D4341 is a benefit when there are four or more teeth in the quadrant that qualify for Scaling and Root Planing

D4342 is a benefit when there are one, two, or three teeth in the quadrant that qualify for Scaling and Root Planing

Never allow D4341 in a quadrant with three or fewer teeth;
R/S to D4342



Adjudication Reason Codes (ARCs)

When Scaling and Root Planing is requested, but no bone loss is observed, we apply **ARC 081**

081: Periodontal procedure cannot be justified on the basis of pocket depth, bone loss, and/or degree of deposits as evidenced by the submitted radiographs

If the periodontal chart suggests deep pockets but radiographs reveal no bone loss, we apply **ARC 081A**

081A: Periodontal evaluation chart does not coincide with submitted radiographic evidence



Adjudication Reason Codes (ARCs)

When the quantity of radiographs is insufficient to allow Scaling and Root Planing, we can apply **ARC 266F**

266F: Payment and/or prior authorization disallowed. Procedure requires current periapicals of the involved areas for the requested quadrant and bitewing radiographs

Scaling and Root Planing can only be authorized once per 24 months. If authorization is requested before then, we apply **ARC 088**. Unfortunately, we are unable to authorize early

088: Procedure is a benefit once per quadrant every twenty-four (24) months.





How to Adjudicate



How to Adjudicate

Evaluate all documentation for evidence of periodontitis

Make sure you are aware of member age

Age 13-20: In most cases there will not be bone loss.

Age 21+: There will probably be some localized areas of bone loss, especially in the 40+ range. Therefore, for this age group we will be leaning more toward allowing D4341 or D4342.

Only deny 081 if there is *clearly* no bone loss



How to Adjudicate

Providers can provide extensive, erroneous, or extraneous documentation, often pertaining to gingivitis rather than periodontitis. When processing, you must see evidence of *periodontitis*.

“ Pt has pain on all gum area due to a lot of calculus and inflamed gum need SRP'S ”

“ Periodontal Charting and X-ray images attached. Loss of attachment evident. Areas with pocketing greater than 6mm, suppuration/inflammation and heavy bleeding upon probing. The tissues are puffy and edematous Sub-gingival calculus present in all quadrants. ”

34. COMMENTS

PAYMENT REQUEST MUST HAVE RENDERING PROV ID

please review, pt does need help cleaning due to pt bleeds when brushing. pt in pain. please review

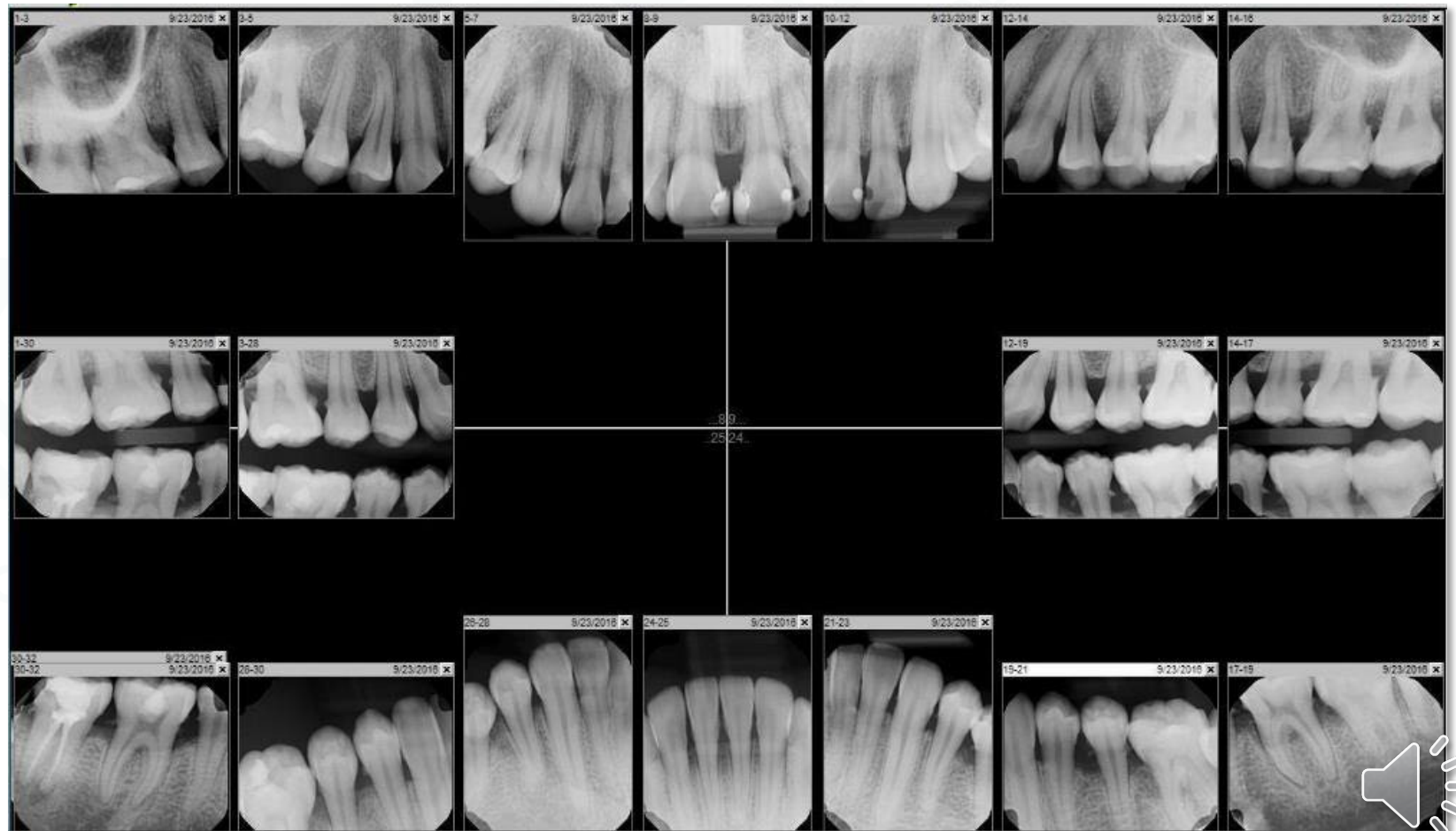
Do not deny based on a bad narrative; evaluate the evidence you have – the member might still have periodontitis



How to Adjudicate

High Quality Radiographs

Here is an example of a case that clearly qualifies for four quadrants of D4341



How to Adjudicate

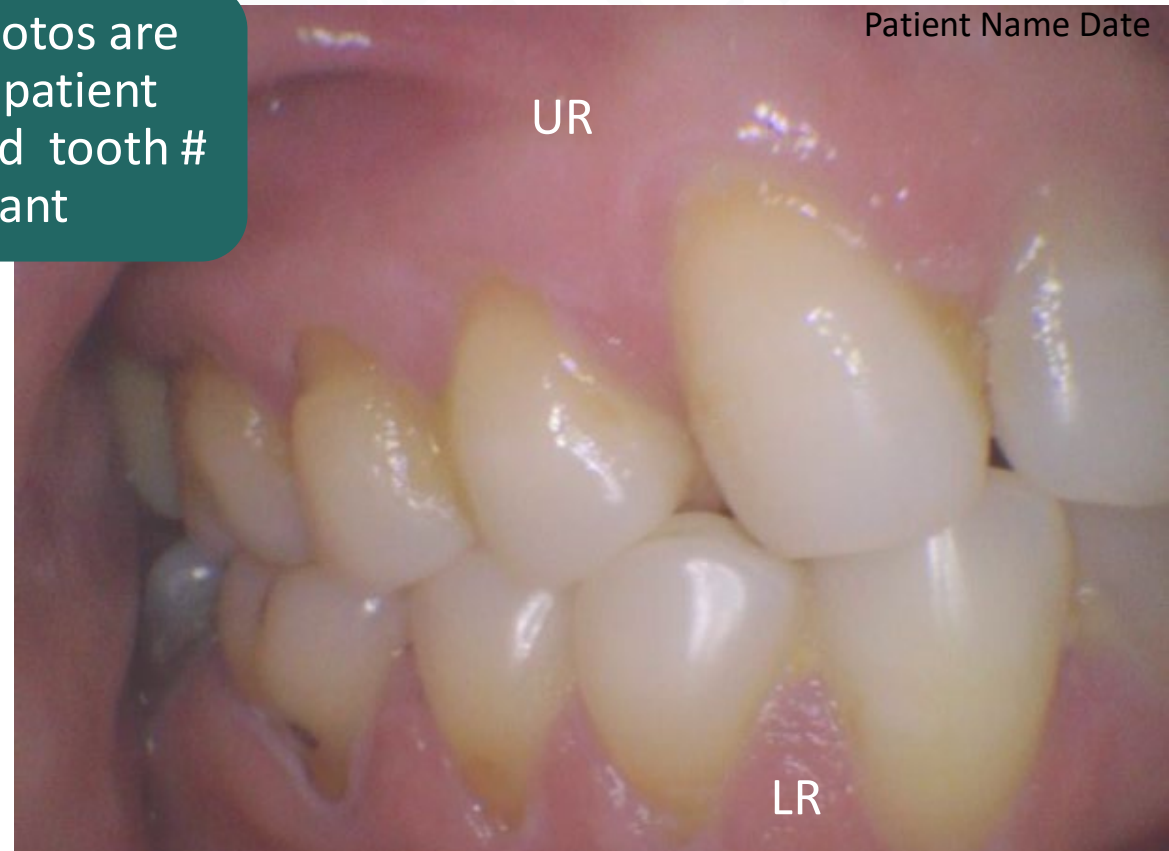
Photographs

Photos can help demonstrate that cementum is exposed and thus available for root planing

Ensure the photos are labeled with patient name, date, and tooth # or quadrant

On TARs, deny photos that have no Date of Service with 031A

If the submitted photo has no date on its label, it cannot be used for adjudication



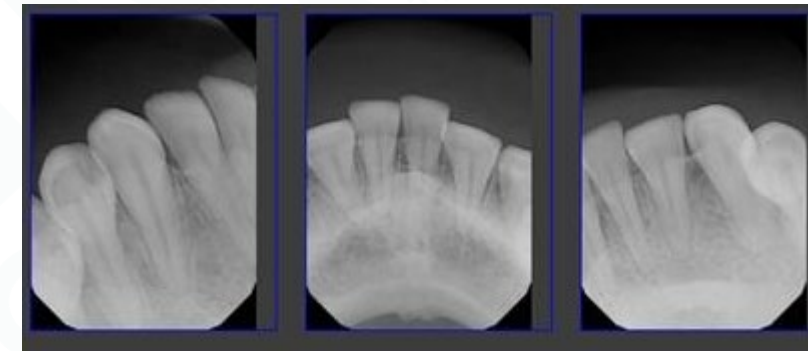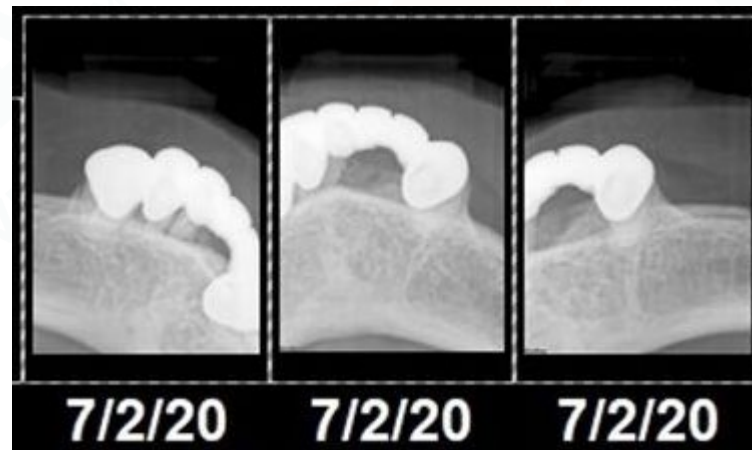
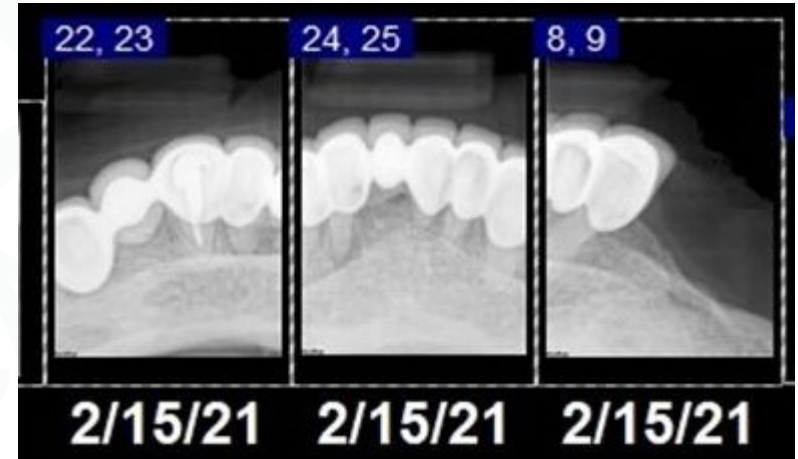
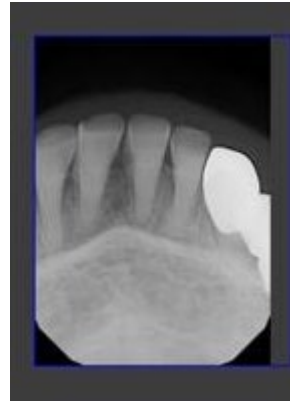Common Problems with Radiographs

Foreshortening

Severe foreshortening prevents evaluation for bone loss

Severe foreshortening prevents evaluation for restorability

ARC 266K



Common Problems

Perio Charting

Dentrix Perio Chart - [8/30/2021]

File View Setup Help

Script: Dentrix Default Script

	1	2	3	4	5	6	7	8	9	10	11	12	13	14	15	16
F	0	0	5	4	4	4	4	4	3	4	4	3	4	4	3	3
PD	0	0	5	4	4	4	4	4	3	4	4	3	3	4	4	3
GM	0	0	5	4	4	4	4	4	3	4	4	3	3	4	4	3
CAL	0	0	5	4	4	4	4	4	3	4	4	3	3	4	4	3
MGJ																
FG																
Bld																
Sup																
Sup																
Bld																
FG																
MGJ																
CAL	0	0	6	4	5	5	5	5	4	4	4	4	4	4	3	3
GM	0	0	6	4	5	5	5	5	4	4	4	4	4	4	3	3
PD	0	0	6	4	5	5	5	5	4	4	4	4	4	4	3	3
L																
PMB																
PMB																
L																
PD	0	0	6	5	5	5	4	4	4	4	4	4	3	3	4	3
GM	0	0	6	5	5	5	4	4	4	4	4	4	3	3	4	3
CAL	0	0	6	5	5	5	4	4	4	4	4	4	3	3	4	3
MGJ																
FG																
Bld																
Sup																
Sup																
Bld																
FG																
MGJ																
CAL	0	0	6	4	4	4	4	4	4	4	4	4	4	4	4	3
GM	0	0	6	4	4	4	4	4	4	4	4	4	4	4	4	3
PD	0	0	6	4	4	4	4	4	4	4	4	4	4	4	4	3
F	32	31	30	29	28	27	26	25	24	23	22	21	20	19	18	17

Common Problems

Some software will allow providers to automatically input the same number for probing depth and clinical attachment level (CAL)

This is **automatically inaccurate in all cases where the gingival crest is not exactly at the CEJ**, because probing depth is distance from the bottom of the sulcus or pocket to the gingival crest, but attachment level is measured from a fixed point, the CEJ

If periodontal charting is submitted, it must appear accurate in order to aid in authorization determination

	32	31	30	29	28	27	26	25	24	23																									
GM	0	0	0	6	4	5	5	5	5	5	4	4	4	4	4	3	3	3	4	3	3	3	3	3	3	3	3	3	3	3	3	3	3		
PD	0	0	0	6	4	5	5	5	5	5	4	4	4	4	4	3	3	3	4	3	3	3	3	3	3	3	3	3	3	3	3	3			
L																																			
PMB																																			
L																																			
PD	0	0	0	6	5	5	5	4	4	4	4	4	4	4	3	3	3	3	4	3	3	4	4	3	4	4	3	4	4	3	3	3	3		
GM	0	0	0	6	5	5	5	4	4	4	4	4	4	4	3	3	3	3	4	3	3	4	4	3	4	4	3	4	4	3	3	3	3		
CAL	0	0	0	6	5	5	5	4	4	4	4	4	4	4	3	3	3	3	4	3	3	4	4	3	4	4	3	4	4	3	3	3	3		
MGJ																																			
FG	-	-	-	-	-	-	-	-	-	-	-	-	-	-	-	-	-	-	-	-	-	-	-	-	-	-	-	-	-	-	-	-	-	-	
Bld																																			
Sup																																			
Sup																																			
Bld																																			
FG	-	-	-	-	-	-	-	-	-	-	-	-	-	-	-	-	-	-	-	-	-	-	-	-	-	-	-	-	-	-	-	-	-	-	
MGJ																																			
CAL	0	0	0	6	4	4	4	4	4	4	4	4	4	4	4	3	3	3	3	4	4	3	4	4	3	4	4	3	4	4	3	4	4	3	4
GM	0	0	0	6	4	4	4	4	4	4	4	4	4	4	4	3	3	3	3	4	4	3	4	4	3	4	4	3	4	4	3	4	4	3	4
PD	0	0	0	6	4	4	4	4	4	4	4	4	4	4	4	3	3	3	3	4	4	3	4	4	3	4	4	3	4	4	3	4	4	3	4
F																																			



Common Problems

Inaccurate Diagnosis

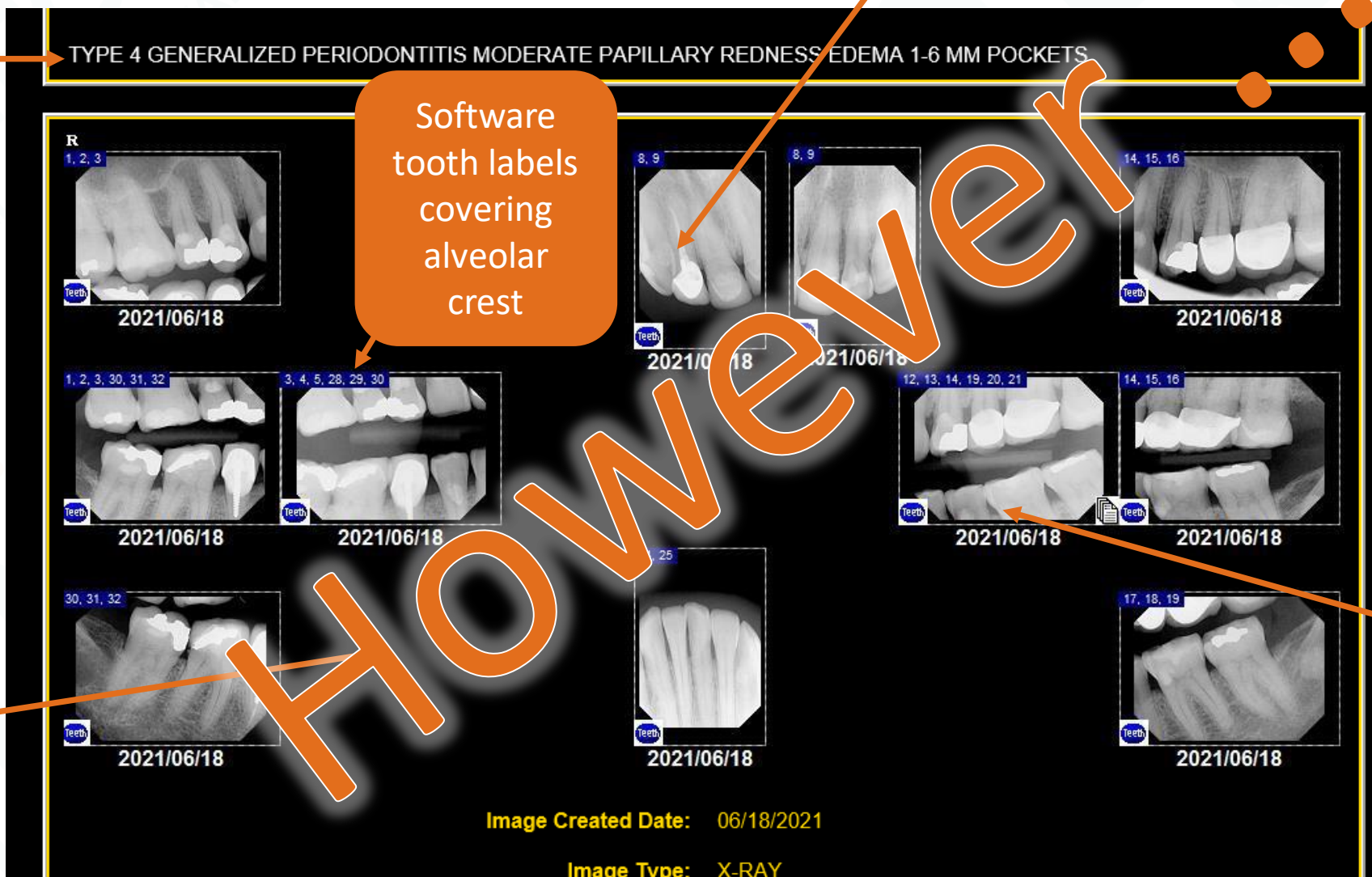TYPE 4 GENERALIZED PERIODONTITIS MODERATE PAPILLARY REDNESS EDEMA 1-6 MM POCKETS

Overlap renders the radiograph nondiagnostic

Software tooth labels covering alveolar crest

Inadequate quantity of periapicals (#27, 28, 29 inadequately covered)

Bitewings not diagnostic due to alveolar crest not captured



Common Problems

There is enough evidence to establish:

Arch Integrity

Four or more restorable teeth per quadrant with bone loss

Four quads of D4341 should be *allowed*

TYPE 4 GENERALIZED PERIODONTITIS MODERATE PAPILLARY REDNESS EDEMA 1-6 MM POCKETS

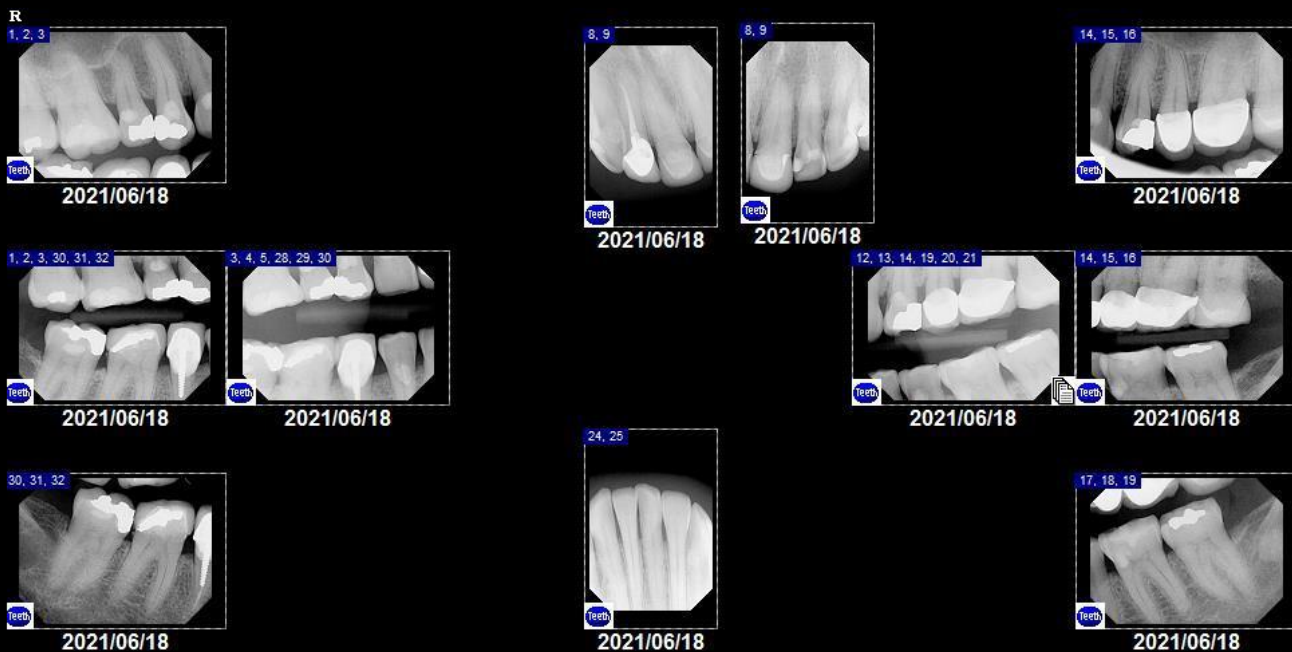

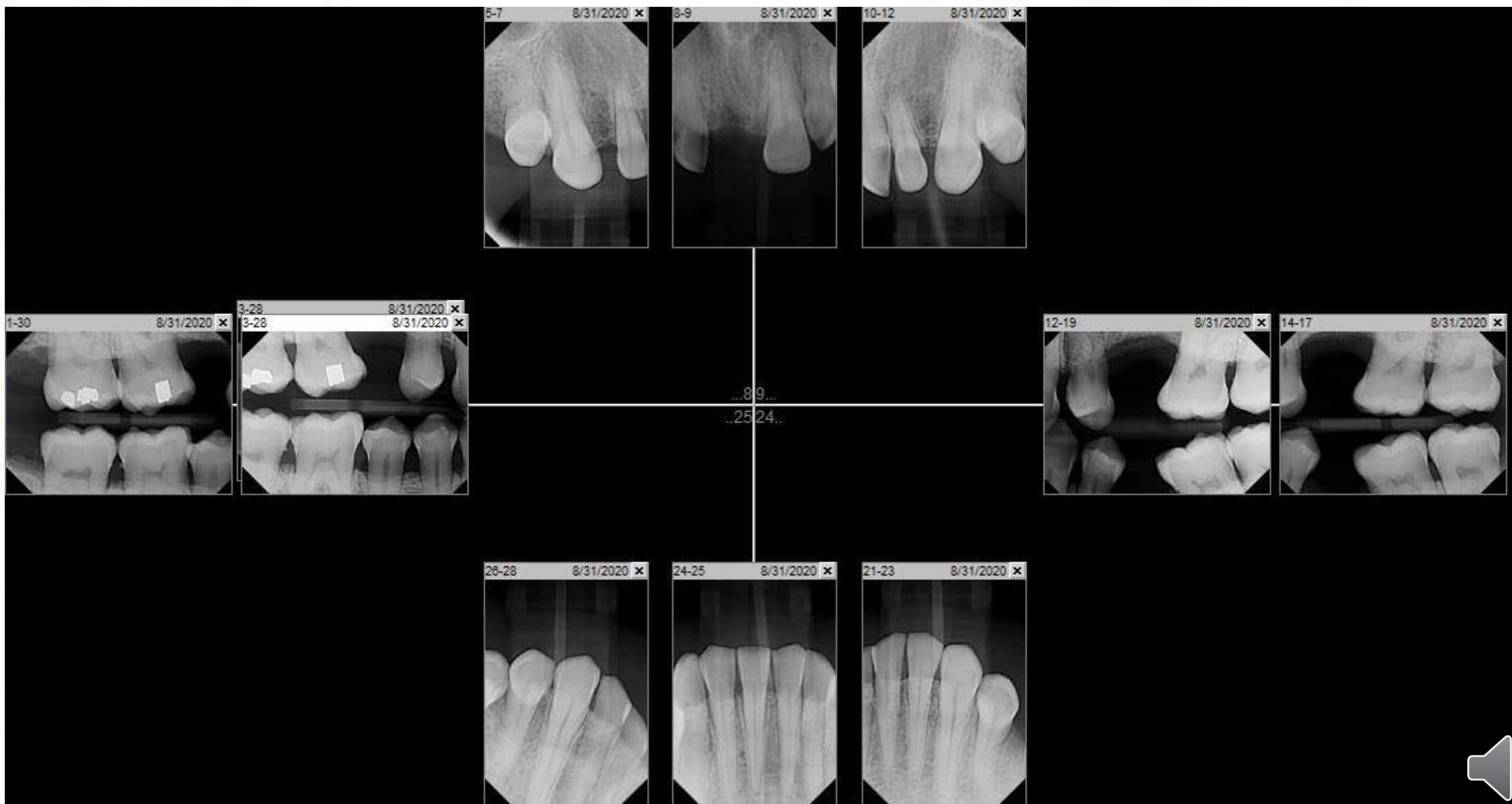
Image Created Date: 06/18/2021

Image Type: X-RAY



More Examples ...

Member is 38 years old



Arch Integrity?

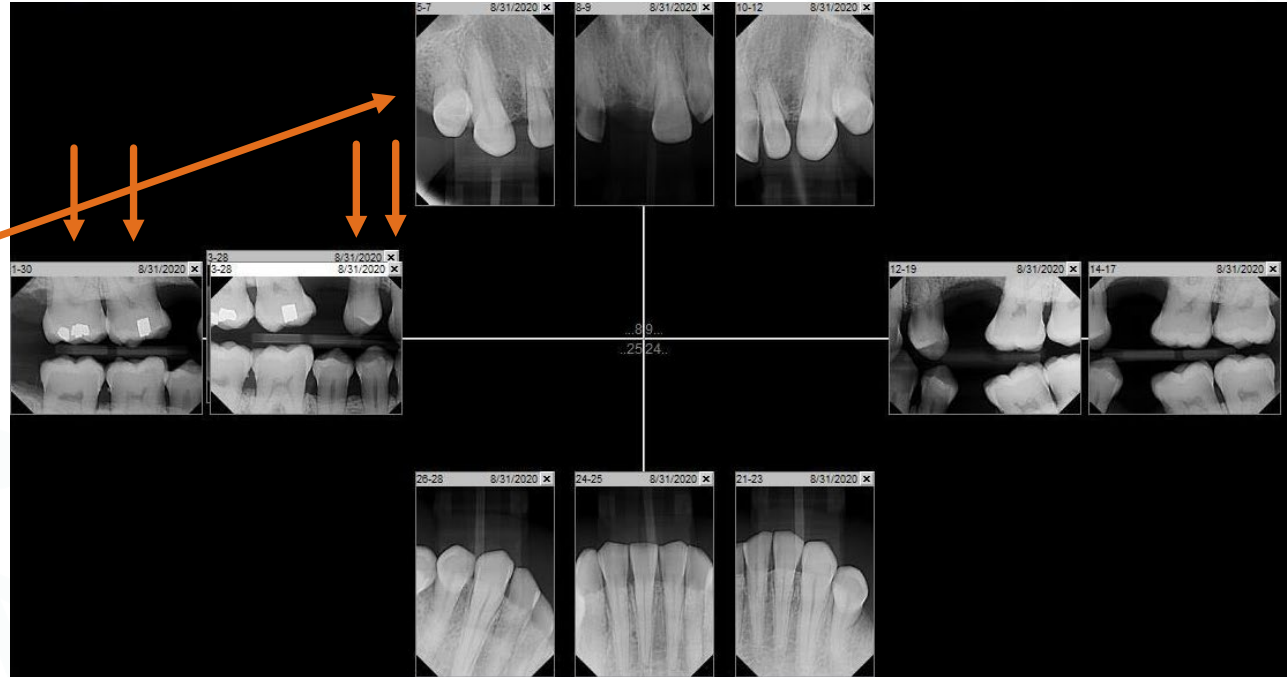
UR:

#2, 3, 5, 6 demonstrate restorability and bone loss on the bitewings

Should we deny 266F?
There's no periapical for #2, 3, and the periapicals for the anterior are foreshortened.

Should we deny 266K?

No! We have already established that the quadrant qualifies

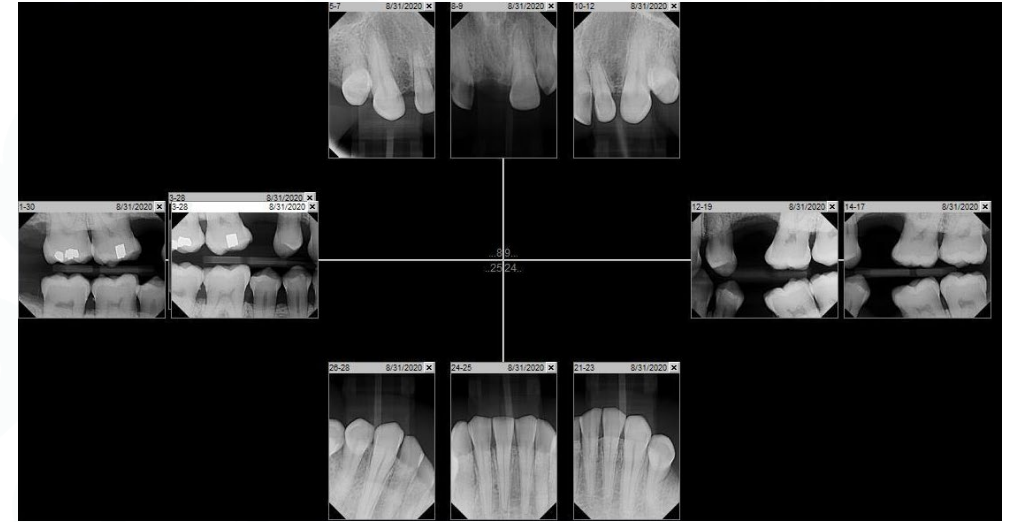


No! The number of periapical radiographs does not meet submission criteria, but we can *correctly adjudicate the document anyway* with these radiographs



In cases where radiographic submissions are inadequate per criteria but are sufficiently diagnostic to adjudicate the case, use what was submitted

However, do not use insufficient radiographs as a reason to downgrade a quadrant to D4342. If the radiographs are truly insufficient, deny the requested treatment

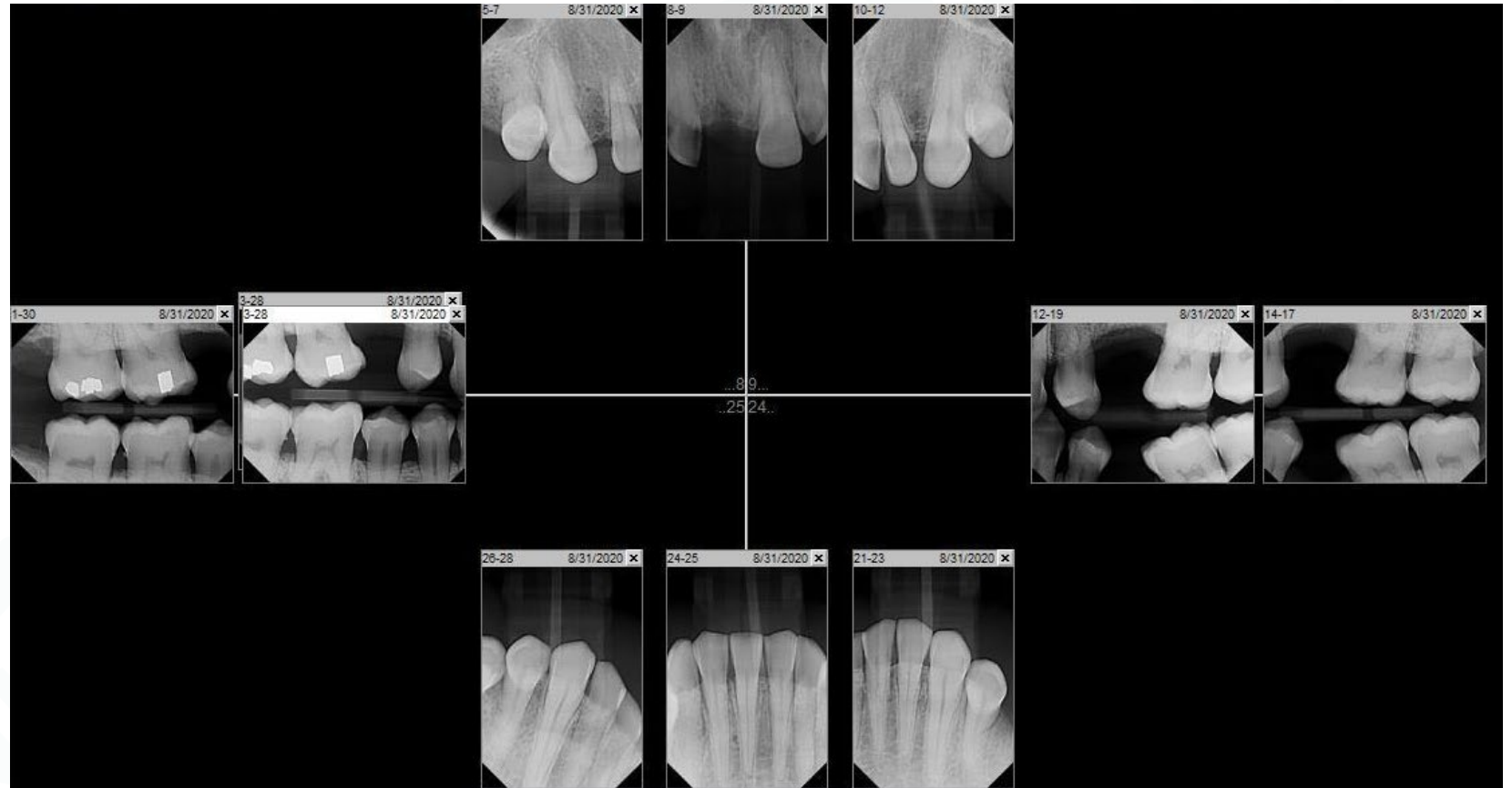


Only downgrade to D4342 when all necessary information to do so *accurately* is available

UR: Allow D4341



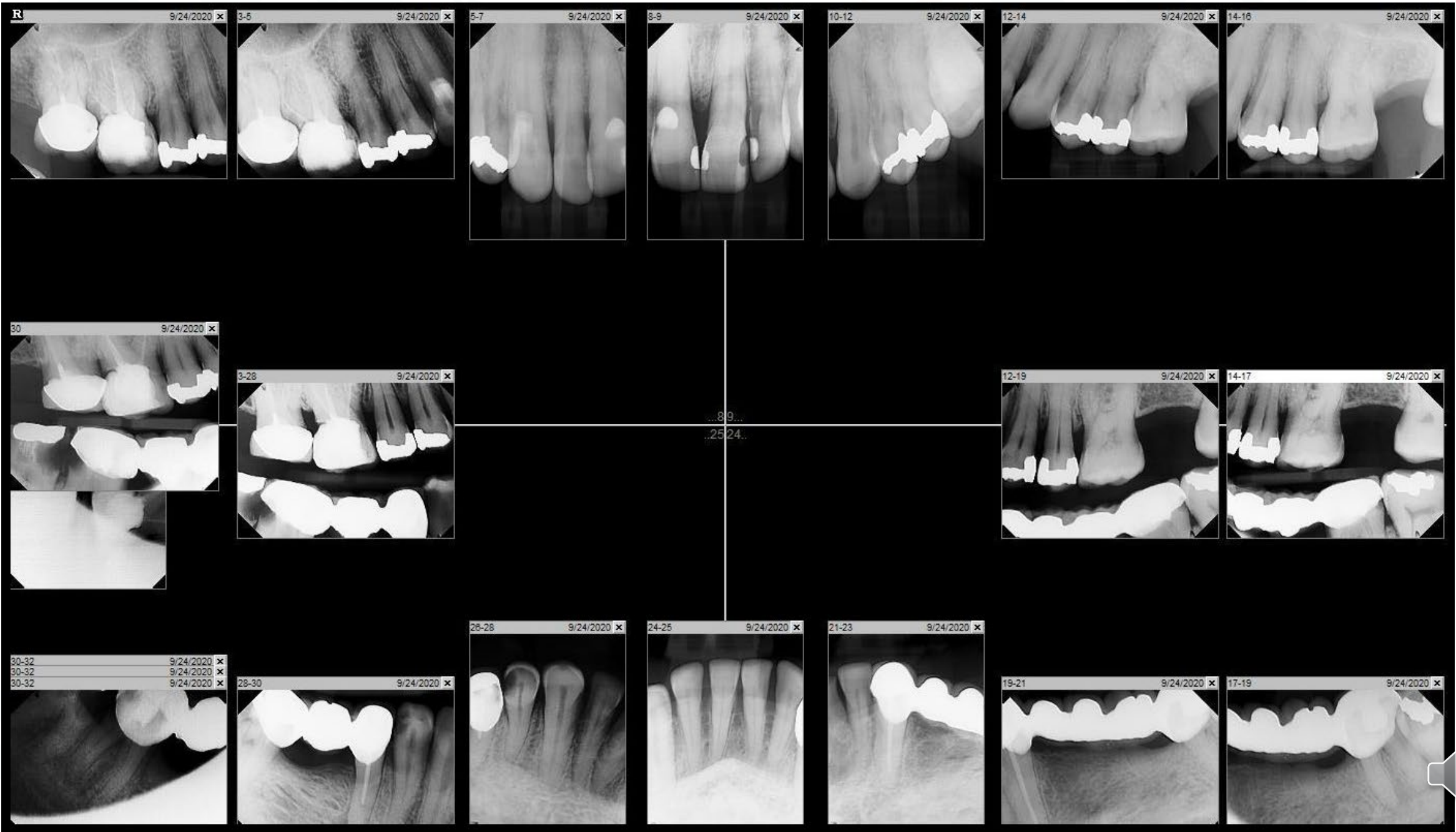
Use the same logic to allow the other three quadrants as well



Allow all 4 quads D4341



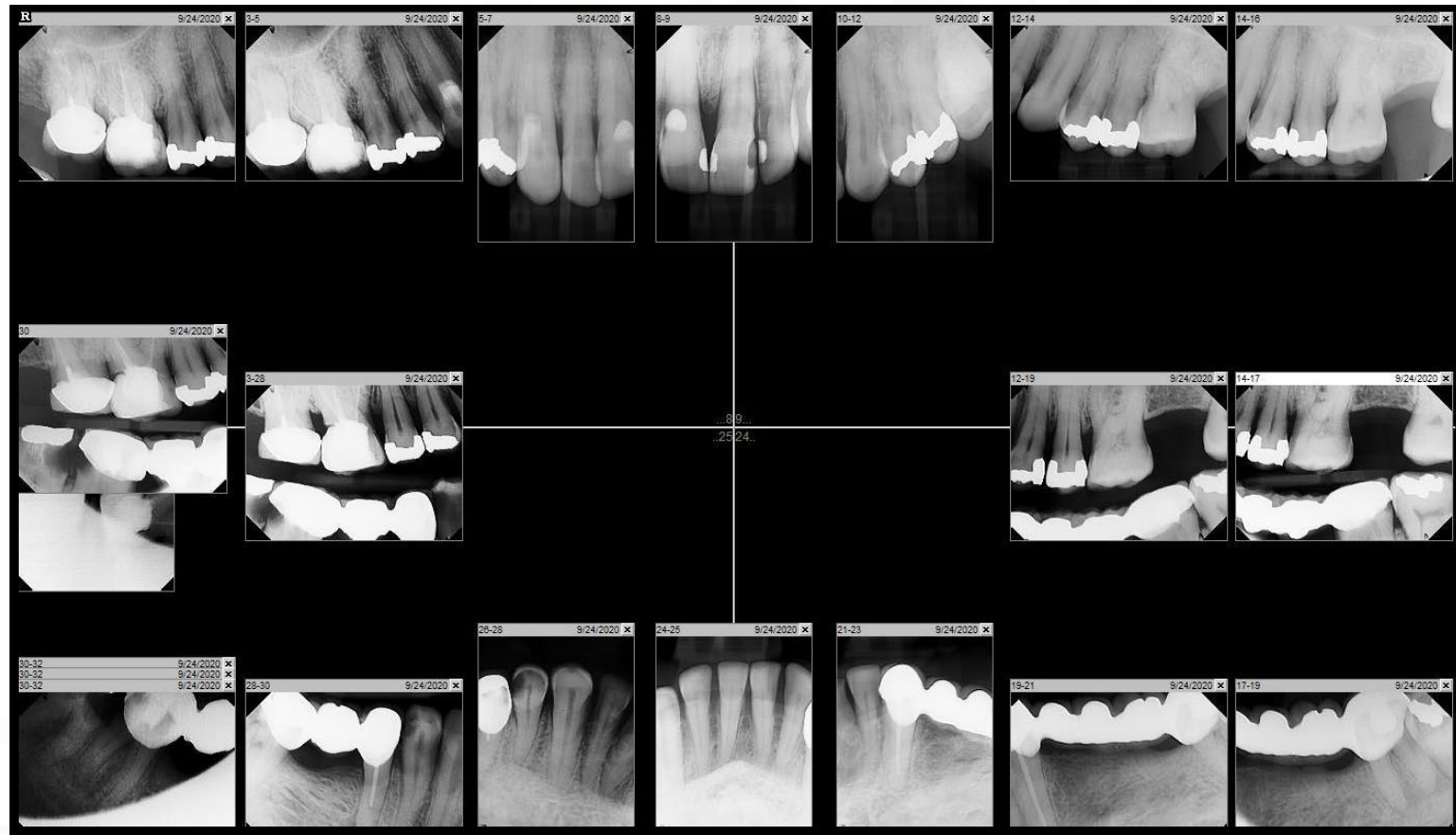




Arch Integrity?

The upper quadrants are easily allowed

Let's look closely at the mandible ...



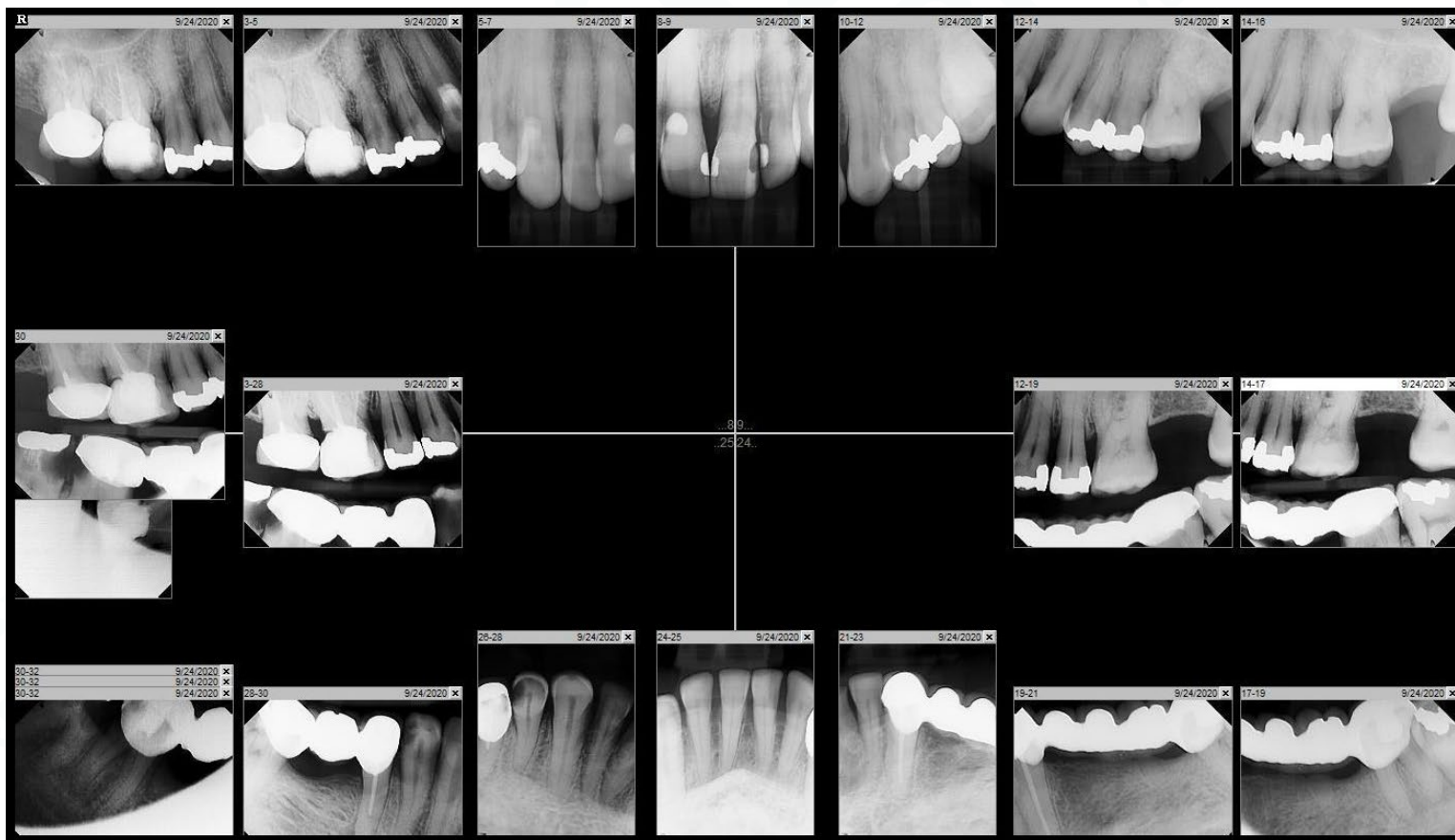
Note that the most distal molar in both quadrants is a third molar; these will not be counted



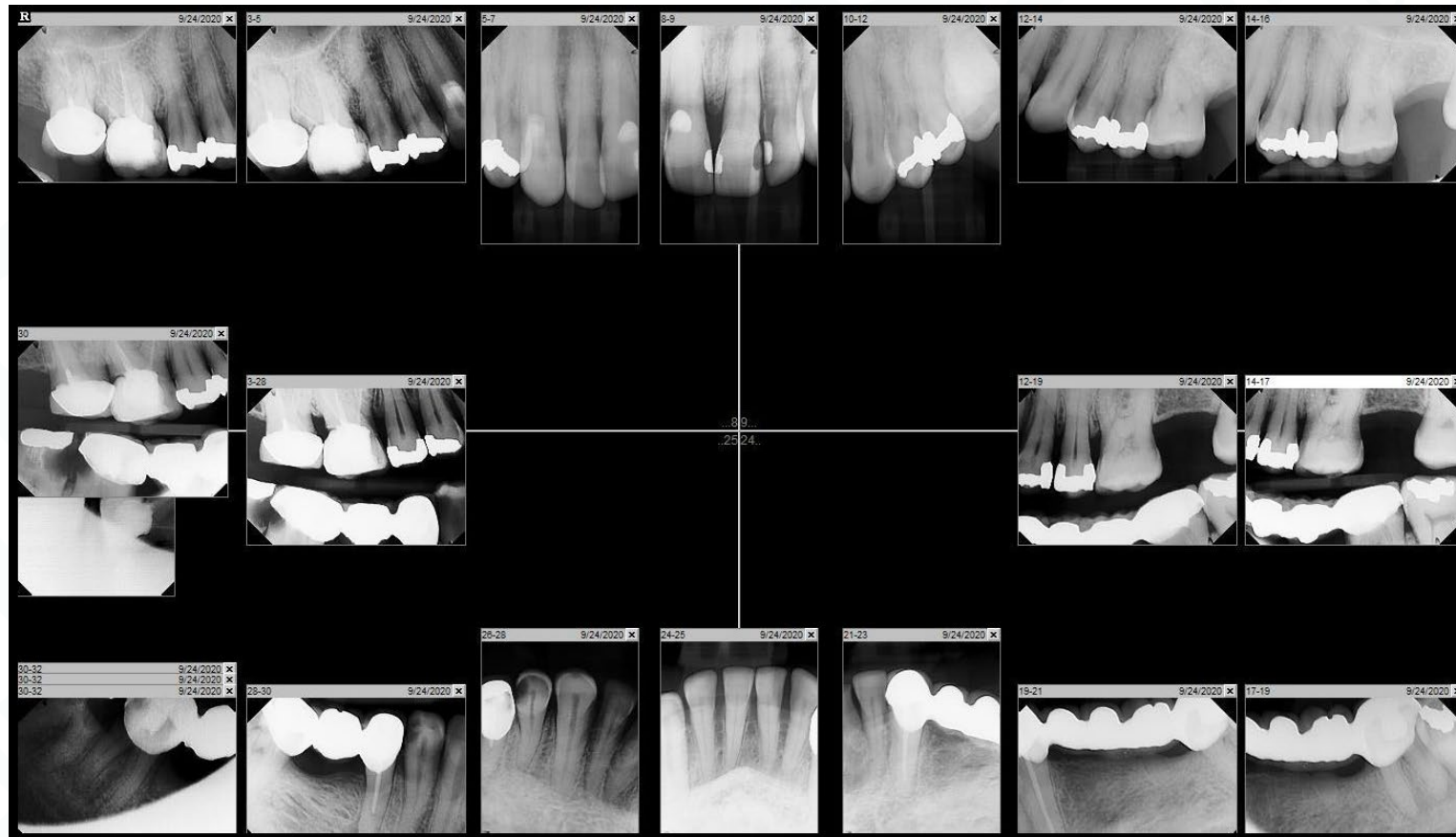
The lower right can be allowed. #27, 28, 29 and #31 can be visualized as restorable and demonstrating bone loss

The lower left is more challenging ...

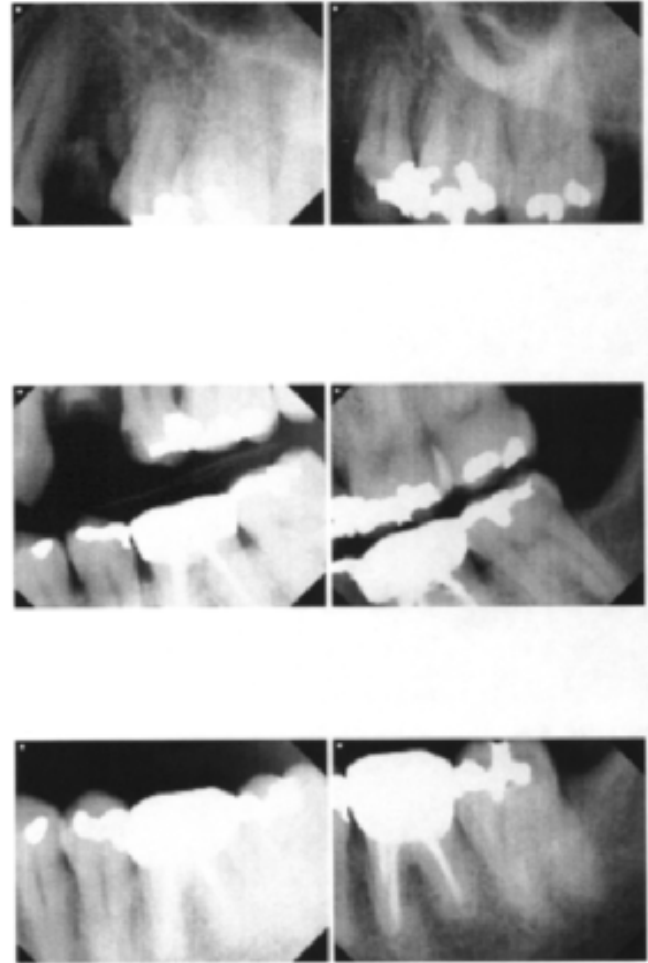
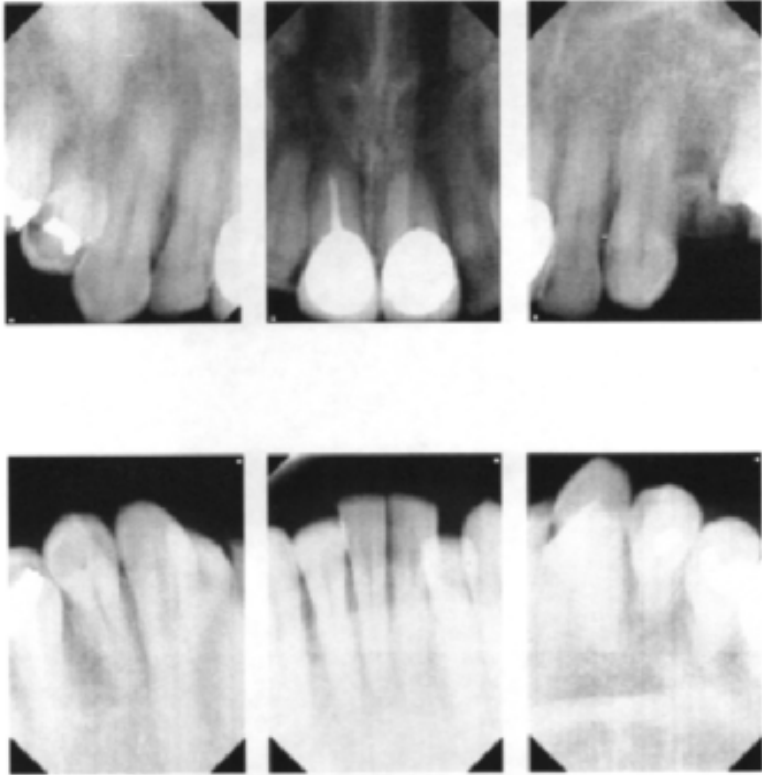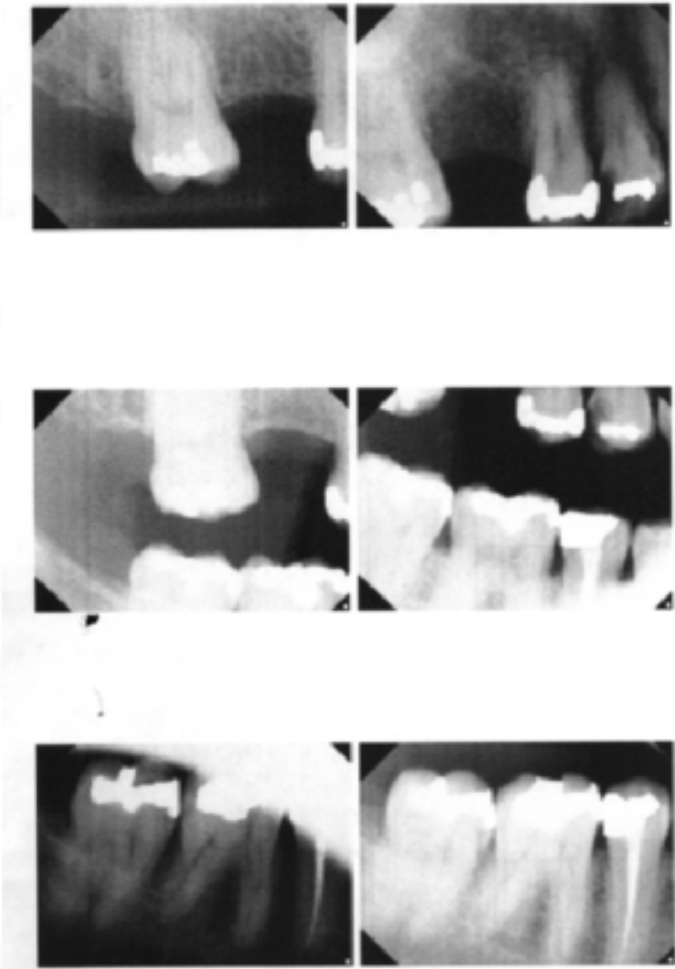
#18 demonstrates bone loss. What about #22, 23, 24?



Given the periodontal status of the rest of the mouth, it would be reasonable to allow four quadrants of D4341 and assume that #22, 23, 24 have some bone loss even though the radiographs are not ideal



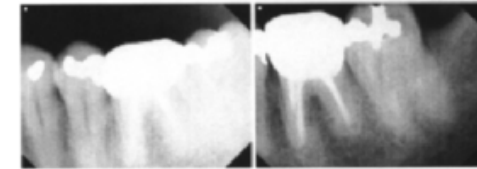
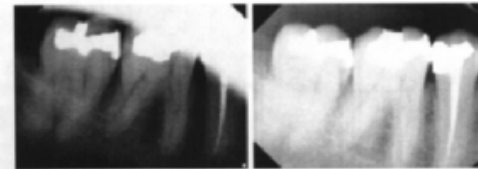
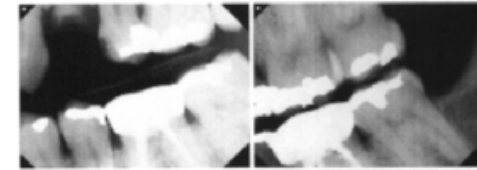
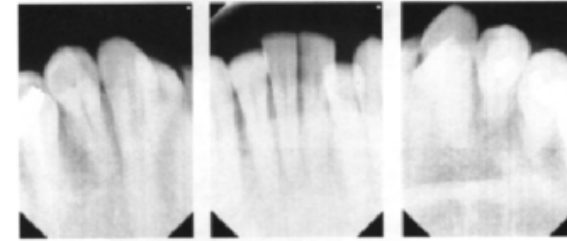
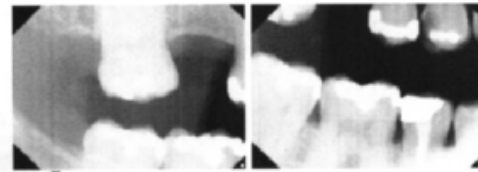
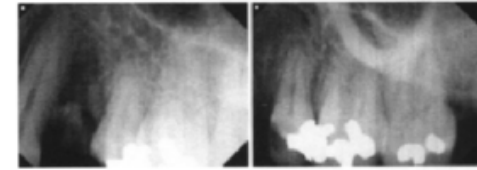
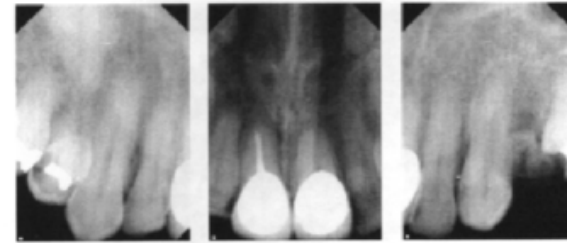
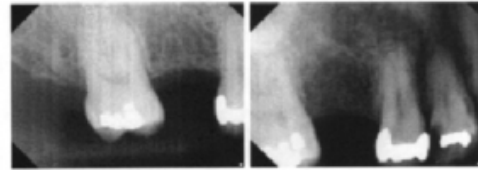




Arch Integrity?

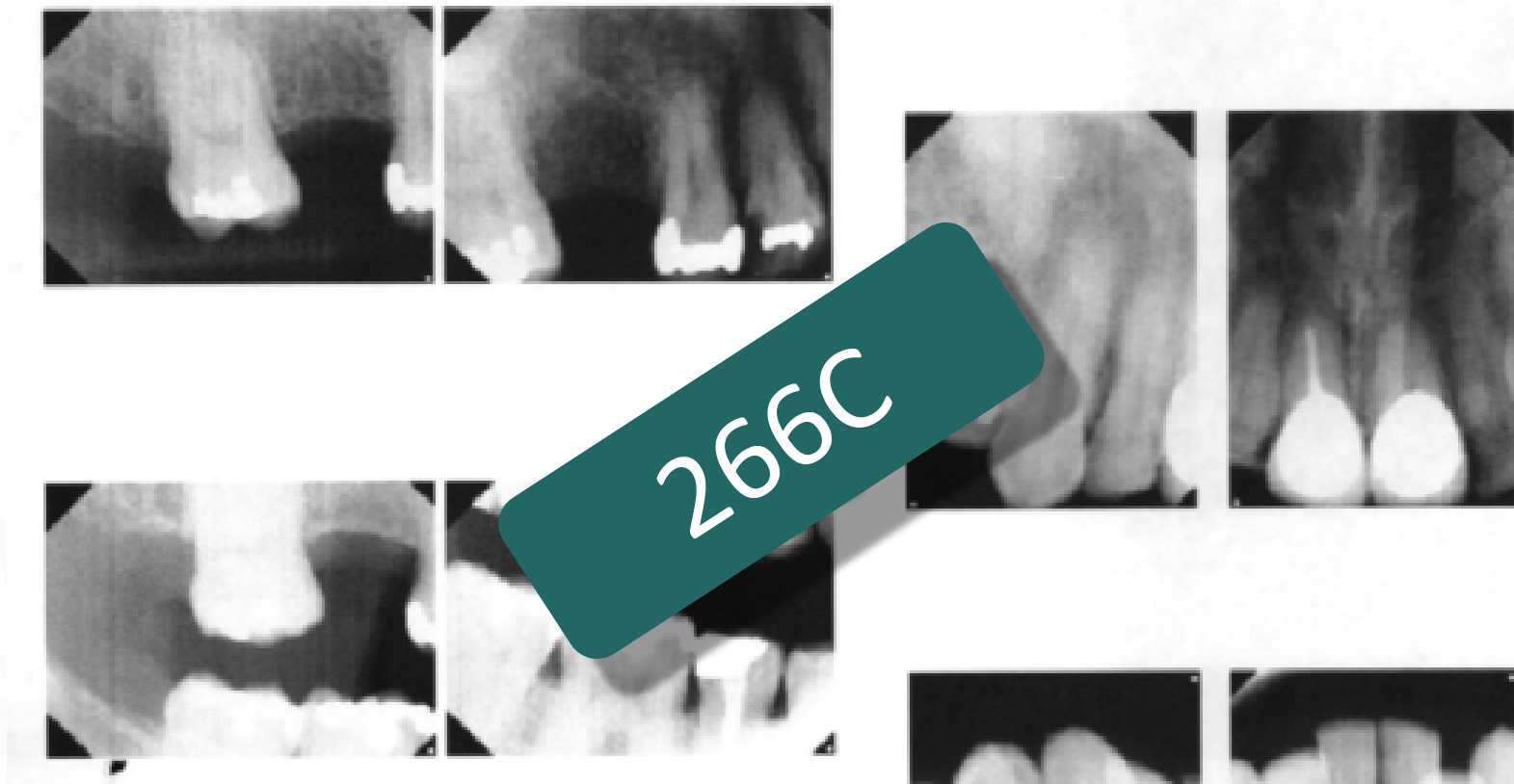
Radiographic quality is not ideal

Let's go quadrant by quadrant, starting with the upper right



Some bone loss can be visualized for #2

Due to poor sensor positioning, bone loss cannot be verified for #4, 5, 6, 7, 8



Although bone loss can be visualized on one tooth, we cannot downgrade to D4342 because we cannot verify whether there is bone loss on other teeth due to poor sensor positioning and foreshortening

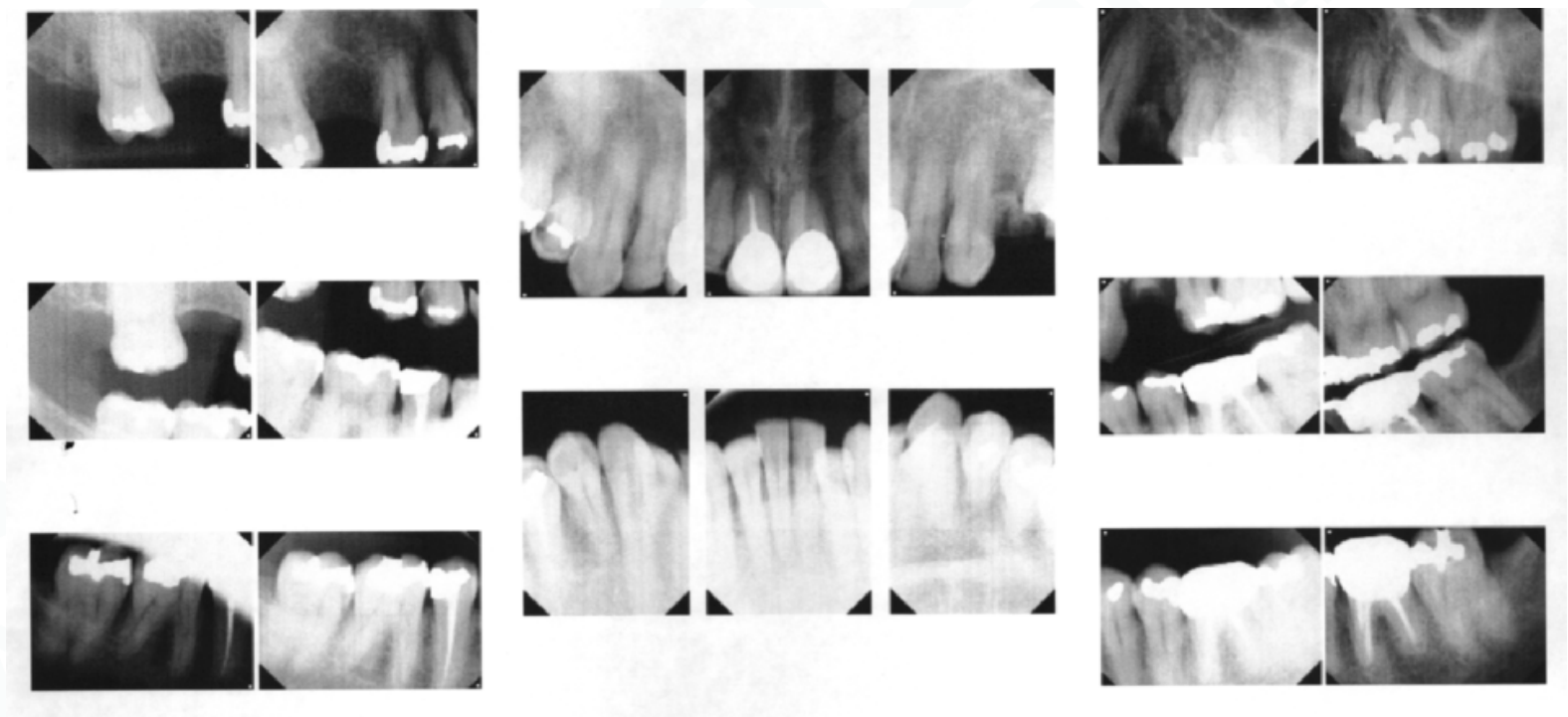




The same logic holds for the rest of the mouth

Generally, we cannot evaluate for whether there are four teeth in each quadrant with bone loss

We must not downgrade to D4342 if we cannot properly evaluate the entire quadrant



266C – all four quadrants





SMILE,
CALIFORNIA™
MEDI-CAL HAS DENTAL COVERED



Summary

Scaling and Root Planing procedures are a benefit when the provider furnishes us evidence that their patient has periodontitis

If “on the fence” and the member is not a child, it is best to allow the procedure

If the correct call can be made even with imperfect radiograph submission, you are encouraged to use your professional judgement to allow

If radiographs are not sufficiently diagnostic to adjudicate correctly, it is preferable to deny the procedure rather than allow on poor evidence





Thank you!

Trainer xxxxxxxxxxx

